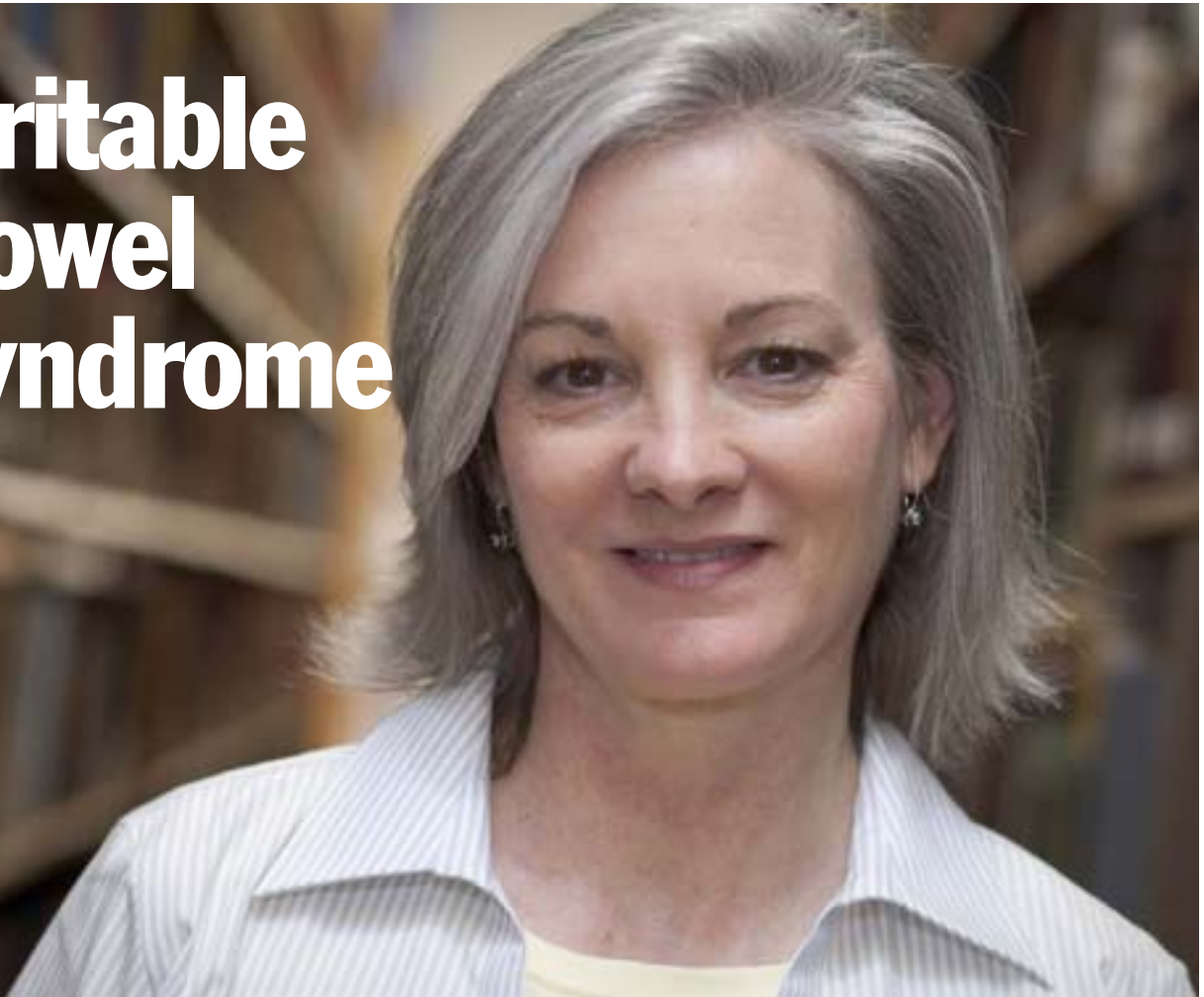


Irritable bowel syndrome



An integrative GP and naturopath team coordinate care to resolve a chronic and complex case of IBS.

Gareth Vanderhope, BNat, is a naturopath and Anthony Solomon, MBBS, FRACGP, is Director, North Coast Medical Centre, Byron Bay and Medical Director, Dharah Gibinj Aboriginal Medical Service, Casino

Anna, a 49-year-old registered nurse, presented to seek advice regarding her previously diagnosed irritable bowel syndrome (IBS). After an initial medical assessment, our integrative GP suggested that a naturopath be involved in her care as he felt that the patient


would have improved outcome using complementary and natural medicines.

Anna supported an integrative approach, so a combined consult with both doctor and naturopath was arranged. The joint consult involved a 30-minute medical and naturopathic exploration of her history and current



SUMMARY

- Collaboration between GP and naturopath is beneficial to patients with chronic conditions
- IBS, common in the community, is a diagnosis of exclusion
- Associated conditions need diagnosis and treatment
- Stool microscopy and culture may produce false negative results
- Emotional factors may also play a role in IBS
- Tailored treatment is more effective than a generalised approach



state of health. The interplay between doctor and naturopath was respectful and equal, allowing the emergence of a diagnostic and treatment direction that would utilise the strengths of both disciplines.

A follow-up consult was arranged later that week with the naturopath so he could conduct an in-depth naturopathic exploration of Anna's case, and a second combined consult to review results of pathology tests.

Various consults (joint and one-on-one) occurred throughout our period of treatment and all patient-related data was entered into Medical Director, which was networked between both practitioners' offices. This allowed them to fulfil their individual roles while working together to provide cohesive integrative care.

Presenting symptoms

Bloating and flatulence with associated pain, loose stools, fatigue and self-diagnosed candida. Bloating occurred throughout the month and was worse premenstrually. Anna woke around 4 or 5 am due to flatulence and managed this with a hot water-bottle.

Loose bowel motions occurred four-to-five times daily, with a sensation of incomplete emptying. Anna's symptoms were worse for dairy, gluten, sugar, alcohol (especially beer and wine) and emotional distress. She experienced mild improvement with period onset, adherence to an 'anti-candida' diet and avoidance of alcohol, dairy and gluten.

History

Anna's severe bloating and loose stools started in 1998 after an excessive intake of beer while on holidays. Since early adulthood, Anna had

experienced mild bouts of bloating.

In 1997, while travelling in Africa, Anna had taken large doses of 'heavy duty' antibiotics for diarrhoeal illness. After swimming in the Zambezi and Nile rivers, she contracted a parasitic infection (*Schistosomiasis*, also known as bilharzia), for which she was treated with praziquantel antiparasitic medication.

Antibiotics were also used during

The interplay between doctor and naturopath was respectful and equal, allowing the emergence of a diagnostic and treatment direction that would utilise the strengths of both disciplines.

Anna's twenties to treat acne. She experienced many bouts of thrush and mild bloating during this time, particularly after antibiotics. She had self-prescribed oral probiotics, which she felt helped to control the thrush.

In 2001, Anna was investigated for bloating and frequent bowel motions with gastroscopy and colonoscopy, which both had normal findings. Stool tests at this time were positive for *Clostridium difficile*, which was isolated on culture and treated with metronidazole (Flagyl).

Past investigations

- Duodenal biopsy: coeliac histology negative and *H. pylori* urease negative
- History of documented iron deficiency
- HSV2 positive
- A Complete Digestive Stool Analysis [CDSA; see *JCM* 2009;8(3):34–6] had been completed by another practitioner in the past, although a copy of the results could not be obtained. According to Anna, no pathogenic organisms were

detected, however she was advised by the practitioner to avoid sugar, alcohol, processed food and to take L-glutamine and protein powders.

Family history

- Father developed bowel cancer in his 70s (still alive)
- Mother and brother have histories of 'irritable bowel syndrome'.

Diagnosis and treatment

Gastrointestinal infection by pathogenic bacteria (*H. pylori*) and parasite (*Cryptosporidium sp.*) as detected by stool antigen testing.

Associated food/chemical sensitivity (gluten, dairy, sugar and alcohol) and functional iron deficiency with underlying IBS.


The GP and naturopath developed a treatment plan that involved sequentially:

1. **Removal** of dietary intolerances, GI pathogens and emotional stressors
2. **Optimisation** of digestion and nutritional status, plus stress-management advice and referral
3. **Restoration** of GI health, microbiota ecology and immune function
4. **Prevention** of further symptoms through education, retesting and monitoring, and addressing other health concerns
5. The **enjoyment** of life, on mental, physical and spiritual levels

Elimination

Medical management for eradication of *H. pylori* was a two-week course of Amoxil (500mg tds), Flagyl (400mg tds) and Losec (20mg bd).

Naturopathic management for eradication of *Cryptosporidium sp.* and supportive treatment of *H. pylori* used




Anna – initial pathology			
Test	Result*	Normal Range	Comments
Full blood count			
Haemoglobin	149g/L	115–165	
WCC	5.8 x 10 ⁹ /L	3.5–12 x 10 ⁹ /L	
Platelets	229 x 10 ⁹ /L	150–400 x 10 ⁹ /L	
MCV	94fL	80–100fL	
Breath hydrogen test (lactose)	Negative	Rise of <20ppm hydrogen	No lactase deficiency
Breath hydrogen test (fructose)	Negative	Rise of <20ppm hydrogen	No fructose deficiency
Urea breath test (<i>H. pylori</i>)	Negative		No upper-GI <i>H. pylori</i> infection
Blood amylase	73	0–100U/L	Normal pancreatic function
Blood lipase	25	0–70U/L	Normal pancreatic function
RAST test (milk, wheat)	Negative		No IgE allergy to milk or wheat
Coeliac screen (TTG IgA antibodies)	<1U/mL	<7U/mL	Negative, however patient on gluten-free diet
Total IgA	3.03g/L	1.24–4.16g/L	Normal range supports validity of coeliac screen
Premenopausal hormonal profile	Normal range		Premenopausal
Ferritin	36mcg/L	30–150ug/L	Low normal
Trans saturation (iron)	17%	20–55%	Functional iron deficiency
Faecal fat	4.8 g/d	0.5–8.0g/d	Malabsorption and maldigestion are less likely
Liver enzyme test	Normal range		Liver pathology unlikely
Stool microscopy and culture	No pathogens, ova, cysts or parasites. Reducing substances not detected		Conventional microscopy and culture may produce false negative results ¹

* Red=high; yellow=low or high-normal; green=normal

Anna – GI function profile (stool antigen testing)			
Incorporating DNA analysis, GC/MS, microscopic, colorimetric, automated chemistry, ELISA tests by Metamatrix			
Test	Result*	Reference range	Comments
<i>Helicobacter pylori</i>	1.4E+008 H	95% ≤1.0E+005	<i>H. pylori</i> antigen present in stool
Anti-gliadin sIgA	19.6	≤12.3mg/dl	Suggests gluten sensitivity
Parasites	<i>Cryptosporidium</i> sp. positive		Parasite infection positive. This may cause bloating, gas, distention and colitis as it affects small bowel brush-border and epithelial lining ²
<i>Lactobacillus</i> sp.	4.7	≥1.2	Normal facultative anaerobes
<i>Bifidobacter</i> sp.	3.1	≥1.8	Normal facultative anaerobes

* Red=high; green=normal



Wormwood Complex, Probiotica, *Euphorbia hirta* and Goldenseal (all Mediherb P/L; Warwick, Queensland), psyllium seed (Nature's Sunshine; Queensland) and lactulose.

The antimicrobials and psyllium were to be taken in three daily doses half an hour before eating and probiotics/lactulose with meals or an hour after eating. Anna was instructed to alternate the antimicrobials throughout a two-month period at the maximum recommended dose.

We advised Anna to reduce saturated fats, refined complex carbohydrates and sugars and to cease dried fruits (especially containing sulphites), dairy products, alcohol (especially wine) and all sources of gluten. She was encouraged to eat a low-GI diet and to include ample freshly crushed garlic with meals. Inclusion of stress-reducing activities, such as yoga, relaxing walks and ongoing counselling, were also encouraged.

Optimisation

- High-quality multivitamin/mineral: 1 cap with food (Femme Essentials; Metagenics, Queensland)
- High-EPA liquid fish oil (Ultra EPA Liquid; Metagenics): 1 tsp (~1600mg EPA/day)
- Zinc citrate (Dr Vera's; BioConcepts, Queensland): 3 caps before bed
- Whey protein isolate (Tony Sfeir's Designer Physique; Elanora, Queensland): 2tbs in smoothie with slightly underripe banana and/or berries
- Hemagenics IC (Metagenics): 1 tablet to maintain iron levels
- Creon Forte 10,000 (Solvay) digestive enzymes: 1–2 caps with each main meal.

Restoration

GI repair:

- Slippery elm powder: 1 tsp 30 mins before each meal
- L–glutamine (Musashi; Nestle): 1 heaped tsp 30 mins before breakfast and lunch, and 1 tsp before bed
- Quercetin and bromelain supplement (Lymphodran Plus; Orthoplex, Queensland): 1 tab 30 mins before meals

Careful history-taking and further investigation did uncover food sensitivity and microbial pathogens, providing us with therapeutic direction and ultimately symptom improvement

- *Lactobacillus acidophilus*, *Bifidobacteria lactis*, colostrum and lactoferrin (Ultra Probioplex; Metagenics): 1 tsp 30 mins before meals
- Organic *Aloe vera* inner leaf juice (Aloe Organics): 60mL/day in divided doses
- Ultra Flora Restore (Metagenics): 1 cap with breakfast and 1 cap before bed

Menstrual balance:

- Chelated magnesium and vitamin B6 (Muscleze; Bioceuticals): 3/day
- Chaste tree (Mediherb): 3 tabs on rising.

Outcomes

After completion of the two-month antimicrobial treatment, Anna commented that she was 'very happy with the progress' because her symptoms had 'improved out of sight'. Her subjective symptom score decreased from 7 (prior to treatment) to 4. She described the improvements as significant reductions in bloating and flatulence (including cessation of associated pain and night waking), and stools were now well formed. Anna appeared more alert and her abdomen was normal for her age,

indeed she no longer looked pregnant. Anna noted ongoing mild bloating worsened by intake of restricted foods or beverages and excessive stress.

Discussion

The presentation of IBS commonly occurs and is a diagnosis of exclusion.³ It is important not to assume that IBS is just 'irritable bowel' as there may be treatable associated pathological processes. Investigating broadly to rule out other significant factors, such as lactose intolerance, is good practice.⁴ In this case study, careful history-taking and further investigation did uncover food sensitivity and microbial pathogens, providing us with therapeutic direction and ultimately symptom improvement.

We are expecting further symptom improvement as the restoration and repair phase of treatment takes effect. However, if this is not the case, further investigative options would include lactulose breath test (for small bowel bacterial overgrowth), abdominal ultrasound (for gallbladder disease), IgG food-allergy testing and re-testing for post-treatment pathogen eradication. Underlying depression, anxiety, or psychosomatisation occurs in greater than 50% of patients presenting for medical attention with IBS, therefore further focus on psychological therapy may have an additional therapeutic role.⁵ ▶

References

- 1 Bruijnesteijn van Coppenraet LE, et al. Clin Microbiol Infect 2009;15(9):869–74.
- 2 Access Medicine. Medical Parasitology. www.access.medicines.com; accessed 18.10.09.
- 3 Murtagh J. General Practice, 4th edn. Melbourne: McGraw Hill, 2007.
- 4 Harrisons Online, Ch 290. Irritable Bowel Syndrome. www.accessmedicine.com; accessed 15.10.09.
- 5 Access Medicine. Gastrointestinal Disorders. www.accessmedicine.com; accessed 15.10.09.